

Case Report

Flexor Pollicis Longus Injury after Corrective Osteotomy of Distal Radius Malunion with Volar Fixed-Angle Plating: Case Report and Review Literature of the Flexor Tendon Injuries after Volar Plating

Arkaphat Kosiyatrakul MD*,
Suriya Luenam MD*, Sunya Prachaporn MD*

* Department of Orthopedics, Phramongkutklao Hospital and College of Medicine, Bangkok, Thailand

Flexor tendon injury is a potential complication after volar plating of distal radius fracture. This article reports a case of flexor pollicis longus tendon rupture after corrective osteotomy of a distal radius malunion with volar fixed-angle plating. Thirty-three cases of flexor tendon injuries after fixed-angle volar plating and eleven cases of flexor tendon injuries after non-fixed-angle volar plating were also reviewed. The clinical presentation, injured tendons, type of the plate, causes of the injuries and preventions of this complication were discussed.

Keywords: Flexor tendon injury, Distal radius fracture, Volar plating

J Med Assoc Thai 2012; 95 (Suppl. 10): S213-S218

Full text. e-Journal: <http://jmat.mat.or.th>

Volar fixed-angle plating for distal radius fracture has become increasingly popular in recent years. Several advantages of this technique including early rehabilitation, direct fracture reduction and minimal soft tissue and less tendon irritation when compared to dorsal approach. This technique is also advantageous in osteopenic patients and for the fracture with metaphyseal comminution, dorsal angulation, intraarticular involvement and in the case of malunion⁽¹⁻⁶⁾. However, this method is not without a problem. The complications of volar fixed-angle plating such as implant failure, joint penetration and tendon ruptures especially flexor pollicis longus are increasing reported^(2,7-15).

The authors report a case of flexor pollicis longus rupture after corrective osteotomy of distal radius malunion with volar fixed-angle plating. The cases of the flexor tendon injuries after fixed- and non-fixed angle volar plating of distal radius fracture were reviewed. The causes and the prevention of the

complication were discussed.

Case Report

A 53-year-old right handed woman sustained a dorsally displaced distal radius fracture. She had a closed reduction and casting for 6 weeks. Physical examination revealed a right wrist deformity. Radiographic evaluation showed a nascent malunion of distal radius with 45 degrees of dorsal tilt, 10 degrees of radial inclination and 15 mm of positive ulnar variance (Fig. 1).

After a routine volar approach and callus removal, the original fracture line and apex of the deformity were easily identified. Though the fracture line was close to the "watershed" area, the osteotomy was performed through the initial fracture line. A 2.4 LCP buttress plate (Synthes) was placed on the "watershed" area of the distal fragment because of the proximity of the osteotomy line and the area. Cancellous iliac bone graft was placed in the osteotomy site. The pronator quadratus muscle was not repaired due to the high-profile characteristic of the plate. Postoperative radiographs were satisfactory with volar tilt of 0 degree, radial inclination of 20 degrees and ulnar variance of 2 mm, however, the plate was not seated properly on the radius. The distal portion of the plate was elevated

Correspondence to:

Kosiyatrakul A, Department of Orthopaedics, Phramongkutklao Hospital and College of Medicine 315 Ratchawithi Road, Bangkok 10400, Thailand.
Phone: 0-2246-0066 Ext 93459, Fax: 0-2644-4940
E-mail: arkaphat@yahoo.com

from the radial styloid (Fig. 2). The osteotomy site was healed at 8 weeks after surgery and the hand and wrist range of motion exercises were allowed as tolerated.

The patient gained wrist flexion/extension arc of 120 degrees, and forearm rotation arc of 150 degrees at 3 months post-operatively.

Three months later, the patient came back with the complaint of loss of active flexion of the right thumb. She had a pain on moving the right thumb 2 weeks prior to this presentation. Physical examination showed tenderness over the prominent part of volar plate. The hardware and alignment of the bone did not change from the initial post-operative radiographs.

Surgical exploration revealed a complete rupture of the flexor pollicis longus tendon. The area of rupture was near to the level of prominent distal edge of the plate (Fig. 3). The flexor carpi radialis and flexor digitorum profundus were intact. The hardware was removed and the flexor pollicis longus tendon was reconstructed with ipsilateral palmaris longus tendon graft. Three months after the second operation, the pinch and grip strength were equal to the contralateral side. Range of motion of the thumb interphalangeal joint was 50% of the contralateral side.

Discussion

Injury of the flexor tendon could occur after volar plating of a distal radius fracture. To our know-

ledge, there are 33 cases reported in the English literature⁽⁸⁻¹⁵⁾. Surprisingly, there are fewer reports of the flexor tendon injuries after non-fixed-angle volar plating. Details of the fixed-angle plate group and non-fixed-angle plate group are showed in the Table 1 and 2,

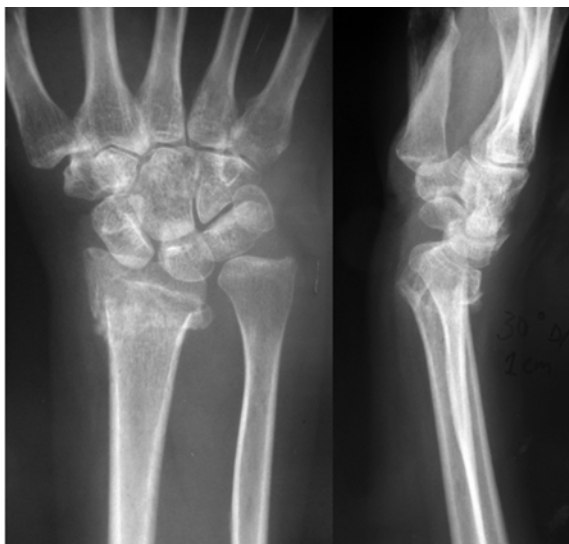

Fig. 1 Posteroanterior (left) and lateral (right) radiograph of the right wrist reveal a dorsally displaced extra-articular distal radius fracture. The fracture is closed to the “watershed” area and surrounded by a callus formation

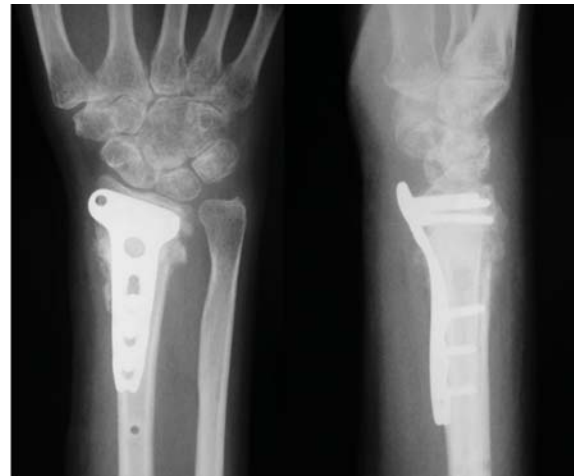

Fig. 2 Postoperative posteroanterior and lateral radiograph reveal an acceptable alignment of the distal radius. The plate was distally placed. The gap between the distal portion of the plate and radial styloid is noted

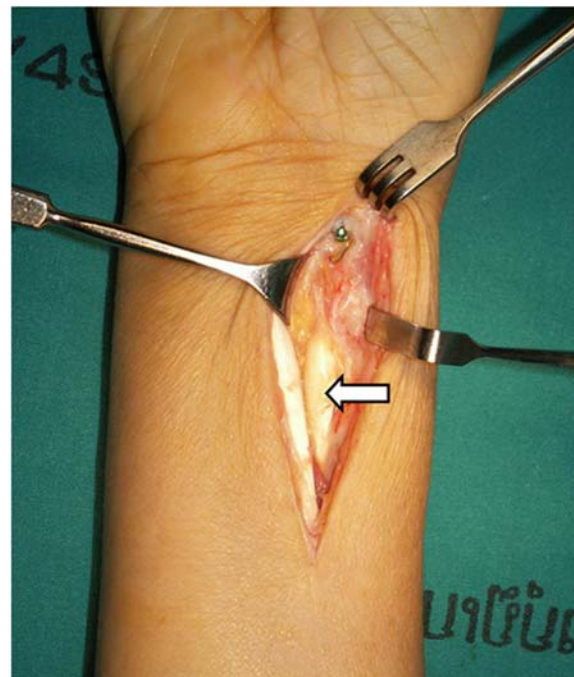


Fig. 3 Intraoperative photograph shows flexor pollicis longus (arrow) ruptured near the distal plate edge

Table 1. Detail of the patients with flexor tendon injuries after volar fixed-angle plating of distal radius fractures

Type of the treatment (cases)	
- acute distal radius fracture [8-15]	32
- corrective osteotomy [11,PR]	2
Time to presentation of the initial symptom (months)	
- mean (range) [8,9,11-15,PR]	12.8 (3-72)
- median [9,11,13-15,PR]	6.5
- not documented [10]	2
Time to presentation of the complete tendon rupture (months)	
- mean (range) [8,9,11,13-15,PR]	9.9 (3-27)
- median [9,11-15,PR]	6
Present of the pre-ruptured symptoms (cases)	
- Yes [9,13,15,PR]	4
- No [11]	1
- Not documented [8,12-14]	24
Injured tendon(s) (cases)	
- Isolate tendon injury	
a. complete FPL ruptured [8,12,14,15,PR]	15
b. incomplete FPL ruptured [11,13]	2
- Multiple tendon injuries	
a. complete FPL rupture and incomplete index FDP rupture [8,9,11]	3
b. complete index FDP and FDS rupture and incomplete middle finger FDP and FDS rupture [13]	1
c. complete FPL rupture and incomplete FCR rupture [13]	1
d. Tenosynovitis [12,13]	10
e. incomplete FCR rupture and FPL subluxation [10]	2
Type of plates (cases)	
- Mathys plate (Synthes) [8]	6
- Synthes volar plate (Synthes) [9,13]	2
- DVR plate plate (Hand Innovations) [11,13,15]	3
- Acu-Loc plate (Acumed) [11,13,14]	4
- 2.4 LCP plate (Synthes) [12,14]	15
- Viper volar plate (Kinetikos Medical) [13]	1
- 2.4 LCP buttress plate (Synthes) [PR]	1
- not documented [10]	2
Causes of the tendon injury (cases)	
- improper implant design [8]	6
- prominent screw head [14]	1
- improper plate placement	
a. distal placement of the plate [9,11,14]	6
b. improper seated of the plate [13,14]	4
c. combine of the two [14,PR]	2
- proper plate placement [13,15]	3
- not documented [10,12]	12

[] = reference(s), PR = the present study, FPL = flexor pollicis longus, FDS = flexor digitorum superficialis, FDP = flexor digitorum profundus

respectively.

The average time to presentation of the tendon rupture was 9.9 months (range 3-27) in the fixed-angle plate group and 20.7 months (range 4-68) in the non-fixed angle plate group. Some of the ruptures occur without any warning symptom. In both groups, the most common tendon injury is the flexor pollicis longus

and the most common cause of tendon injury is the improper plate placement, especially the distal placement of the plate. Regarding this, the plate should be place on the concavity of the distal radius proximal to the “watershed” area or the transverse ridge⁽¹⁶⁾. However, placement of the volar plate was influenced by the fracture pattern, the plate design and the

Table 2. Clinical features of patients with flexor tendon injuries after non-locking volar plating of distal radius fractures

Type of the treatment (cases)	
- ORIF of acute distal radius fracture [17-22]	11
Time to presentation of the initial symptom (months)	
- mean (range) [17-22]	19.3 (4-68)
- median [17-22]	9
Time to presentation of the complete tendon rupture (months)	
- mean (range) [17-22]	20.7 (4-68)
- median [17-22]	9.5
Present of the pre-ruptured symptoms (cases)	
- Yes [18,20]	3
- No [17-19]	4
- Not document [17,20,22]	4
Injured tendon(s) (cases)	
- Isolate tendon injury	
a. complete FPL ruptured [17-22]	7
b. incomplete FPL ruptured [18,20]	2
c. complete index FDP rupture [17]	1
- Multiple tendon injuries	
a. complete FPL rupture and incomplete index FDP rupture [18]	1
Type of plates (cases)	
- Volar buttress plate (Synthes) [18,20,22]	6
- Synthes volar plate (Synthes) [20]	2
- Ellis plate [17]	2
- Synthes dorsal (Pi) plate (Synthes) [19]	1
Causes of the tendon injury (cases)	
- improper plate placement	
a. distal placement of the plate [17,18,20]	6
- collapsing of the fracture [18,21,22]	4
- wrong indication [19]	1

[] = reference(s), FPL = flexor pollicis longus, FDS = flexor digitorum superficialis, FDP = flexor digitorum profundus

manufacturer's recommendation⁽⁹⁾. If the fracture line is closed to the "watershed" area, placement of the volar plate on the area may be unavoidable. Moreover, some plates were designed to place on the "watershed" area.

Secondary collapse of the fracture may also lead to plate malposition. After the fracture was collapsed, the initial position was changed and the distal end of the plate would become more prominent^(18,21,22). This could be occurred in the non-fixed angle plate groups. Fixed-angle plate can prevent the secondary collapse; however, distal limb of the plate should be seated with the distal fragment as much as possible because distal radius is surrounded by highly mobile tendons. Placing of the first locking screw in the distal limb of the plate is also critical. If the plate was not seated on the distal fragment properly when the first locking screw was completely fit, the plate will not seat with the bone.

In the present case, fixation of the osteotomy was performed by volar fixed angle plate with non structural bone graft. The authors preferred the 2.4 LCP buttress plate (Synthes) over the low profile 2.4 LCP juxta-articular because even a thicker plate has been broken⁽⁷⁾. This plate is a high profile version of the juxta-articular one but still allow placement of the plate close to joint with a low risk of intra-articular screw penetration.

Malposition of the plate resulted in rupture of the flexor pollicis longus tendon in our patient. Placement of the plate beyond the 'watershed' area lead to prominent of the distal part of the plate distally and particularly on the radial aspect, combined with thickness of the plate both increased the risk of flexor tendon injury. As mentioned, injury is more vulnerable to more radial tendon-the flexor pollicis longus.

To prevent the flexor tendon injuries after volar fixed angle plating, placement of the plate on the

watershed area should be avoided if possible^(9,11,13,16). The pronator quadratus muscle should be repaired back after plating was successful^(9,13). The distal limb of the plate should be seated with the distal fragment as much as possible.

Finally, in the case of improper plate placement, the implant should be removed as soon as the bone is united because there were reports of tendon ruptures without warning symptoms^(11,13,17-19). Flexor tendon injury after proper plate placement has also been reported. In this group if patient experienced pain, swelling or crepitus over the plate, patient should return for plate removal without any hesitation.

Potential conflicts of interest

None.

References

1. Smith DW, Henry MH. Volar fixed-angle plating of the distal radius. *J Am Acad Orthop Surg* 2005; 13: 28-36.
2. Malone KJ, Magnell TD, Freeman DC, Boyer MI, Placzek JD. Surgical correction of dorsally angulated distal radius malunions with fixed angle volar plating: a case series. *J Hand Surg Am* 2006; 31: 366-72.
3. Henry M. Immediate mobilisation following corrective osteotomy of distal radius malunions with cancellous graft and volar fixed angle plates. *J Hand Surg Eur Vol* 2007; 32: 88-92.
4. Osada D, Kamei S, Takai M, Tomizawa K, Tamai K. Malunited fractures of the distal radius treated with corrective osteotomy using volar locking plate and a corticocancellous bone graft following immediate mobilisation. *Hand Surg* 2007; 12: 183-90.
5. Slagel BE, Luenam S, Pichora DR. Management of post-traumatic malunion of fractures of the distal radius. *Orthop Clin North Am* 2007; 38: 203-16.
6. Berglund LM, Messer TM. Complications of volar plate fixation for managing distal radius fractures. *J Am Acad Orthop Surg* 2009; 17: 369-77.
7. Yukata K, Doi K, Hattori Y, Sakamoto S. Early breakage of a titanium volar locking plate for fixation of a distal radius fracture: case report. *J Hand Surg Am* 2009; 34: 907-9.
8. Drobetz H, Kutscha-Lissberg E. Osteosynthesis of distal radial fractures with a volar locking screw plate system. *Int Orthop* 2003; 27: 1-6.
9. Klug RA, Press CM, Gonzalez MH. Rupture of the flexor pollicis longus tendon after volar fixed-angle plating of a distal radius fracture: a case report. *J Hand Surg Am* 2007; 32: 984-8.
10. Rozental TD, Blazar PE. Functional outcome and complications after volar plating for dorsally displaced, unstable fractures of the distal radius. *J Hand Surg Am* 2006; 31: 359-65.
11. Cross AW, Schmidt CC. Flexor tendon injuries following locked volar plating of distal radius fractures. *J Hand Surg Am* 2008; 33: 164-7.
12. Jupiter JB, Marent-Huber M. Operative management of distal radial fractures with 2.4-millimeter locking plates. A multicenter prospective case series. *J Bone Joint Surg Am* 2009; 91: 55-65.
13. Adham MN, Porembski M, Adham C. Flexor tendon problems after volar plate fixation of distal radius fractures. *Hand (N Y)* 2009; 4: 406-9.
14. Casaletto JA, Machin D, Leung R, Brown DJ. Flexor pollicis longus tendon ruptures after palmar plate fixation of fractures of the distal radius. *J Hand Surg Eur Vol* 2009; 34: 471-4.
15. Lifchez SD. Flexor pollicis longus tendon rupture after volar plating of a distal radius fracture. *Plast Reconstr Surg* 2010; 125: 21e-3e.
16. Orbay J. Volar plate fixation of distal radius fractures. *Hand Clin* 2005; 21: 347-54.
17. Fuller DJ. The Ellis plate operation for Smith's fracture. *J Bone Joint Surg Br* 1973; 55: 173-8.
18. Bell JS, Wollstein R, Citron ND. Rupture of flexor pollicis longus tendon: a complication of volar plating of the distal radius. *J Bone Joint Surg Br* 1998; 80: 225-6.
19. Nunley JA, Rowan PR. Delayed rupture of the flexor pollicis longus tendon after inappropriate placement of the pi plate on the volar surface of the distal radius. *J Hand Surg Am* 1999; 24: 1279-80.
20. Douthit JD. Volar plating of dorsally comminuted fractures of the distal radius: a 6-year study. *Am J Orthop (Belle Mead NJ)* 2005; 34: 140-7.
21. Koo SC, Ho ST. Delayed rupture of flexor pollicis longus tendon after volar plating of the distal radius. *Hand Surg* 2006; 11: 67-70.
22. Duncan SF, Weiland AJ. Delayed rupture of the flexor pollicis longus tendon after routine volar placement of a T-plate on the distal radius. *Am J Orthop (Belle Mead NJ)* 2007; 36: 669-70.

รายงานผู้ป่วยเส้นเอ็น flexor pollicis longus บาดเจ็บภายหลังการผ่าตัดแก้ไขความผิดปกติของกระดูก radius ส่วนปลายด้วย plate ชนิด volar fixed-angle และทบทวนบทความเรื่องการบาดเจ็บของเส้นเอ็น flexor ภายหลังการใส่ plate ด้าน volar

อรรถพัลล์ โกสิยตระกูล, สุริยา ลือนาม, สัญญา ประชาพร

การบาดเจ็บของเส้นเอ็น flexor ภายหลังการใส่ plate ด้าน volar เป็นภาวะแทรกซ้อนที่สามารถพบได้ บทความนี้รายงานผู้ป่วยเส้นเอ็นนิ้วหัวแม่มือ flexor pollicis longus ขาดภายหลังการผ่าตัดแก้ไขความผิดปกติของกระดูก radius ส่วนปลายด้วย plate ชนิด volar fixed-angle พร้อมกับได้ทบทวนบทความที่รายงานถึงการบาดเจ็บต่อเส้นเอ็น flexor ที่เกิดจากการใส่ plate ด้าน volar ทั้งอาการทางคลินิก เส้นเอ็นที่ได้รับบาดเจ็บ ชนิดของ plate ที่ใช้ สาเหตุของการบาดเจ็บ และการป้องกันภาวะแทรกซ้อนดังกล่าว
