

Case Report

Modified Uniportal Endoscopic Plantar Fasciotomy: A Technical Report

Chayanin Anghthong MD*, Chatchavan Charoenthamruksa MD**,
Sukanis Chumchuen MD*, Supakit Kanitnate MD*,
Anuwat Khadsongkram MD*, Wirana Anghthong MD***

* *Foot and Ankle Surgery, Department of Orthopedic Surgery, Faculty of Medicine,
Thammasat University, Pathumthani, Thailand*

** *Department of Orthopedic Surgery, HRH Princess Maha Chakri Sirindhorn Medical Center,
Faculty of Medicine, Srinakharinwirot University, Nakhon Nayok, Thailand*

*** *Department of Radiology, HRH Princess Maha Chakri Sirindhorn Medical Center, Faculty of Medicine,
Srinakharinwirot University, Nakhon Nayok, Thailand*

Objective: Several authors have reported the benefits of the recent procedure of the dual portal endoscopic plantar fasciotomy (EPF). However, very little is known concerning its potential capability via the single portal EPF without special cutting device. The present study aimed to demonstrate the effectiveness of uniportal EPF in a patient with severe intractable plantar fasciitis following a failure of several conservative treatments. The recent technique; uniportal EPF under modified method, without a special cutting device, was reviewed in an effort to improve its capability for plantar release and to provide information for the avoidance of this procedure's complications.

Case Report: A patient, with the recalcitrant conditions and the progression of the severe plantar fasciitis of bilateral feet after a failure of the conservative treatments for 13-month period, was included in this report. All data of the preoperative and each successive postoperative period (1, 6 months and last follow-up) were prospectively collected including American Orthopedic Foot and Ankle Society (AOFAS) score, Visual Analogue Scale-Foot and Ankle (VAS-FA) score and any related complications. The operations were carried out by a single surgeon with the modified uniportal EPF via a simple hooked soft-tissue blade, without a special cutting device, on both feet simultaneously. All feet had uniportal EPF with transection of the medial 50% of the plantar fascia. Postoperatively, a patient was instructed to have partial-weight bearing for the first 2 weeks with wearing of full-length silicone insoles. Then, she is allowed to start to fully weightbear with the insoles. She is advised to cautiously return to daily activities and works at 2nd week after the operation. In regard to the EPF in two feet, there were clearly improvements in the comparison between preoperative and last follow-up period in terms of the increasing AOFAS scores, and VAS-FA scores. There were no significant iatrogenic-related complications including the lateral column pain in the present report.

Conclusion: The recalcitrant condition of severe plantar fasciitis is not uncommon for several orthopedic surgeons. Regarding the emerging of several minimally invasive procedures for this condition, our modified uniportal EPF with a simple device was encouraging as a treatment option in releasing the plantar fascia with satisfactory effectiveness and lower risks of complications.

Keywords: Plantar fasciotomy, Endoscopy, Uniportal, Plantar fasciitis, Chronic

J Med Assoc Thai 2012; 95 (Suppl. 10): S219-S225

Full text. e-Journal: <http://jmat.mat.co.th>

Regarding the modern trends for treatment of foot and ankle are toward minimally invasive procedures, various authors have reported benefits of the recent procedure of endoscopic plantar fasciotomy

Correspondence to:

Anghthong C, Foot and Ankle Surgery, Department of Orthopedic Surgery, Faculty of Medicine, Thammasat University, Paholyothin Road, Klong Nueng, Klong Luang, Pathumthani 12120, Thailand.

Phone: 0-2926-9775, Fax: 0-2926-9793

E-mail: chatthara@yahoo.com

(EPF)⁽¹⁻³⁾. This procedure has been stated to be associated with a smaller number of complications⁽⁴⁾ and an earlier return to work⁽⁵⁾ compared to conventional heel spur surgery. Several surgeons have used this procedure for plantar fascia release under numerous conditions with intractable plantar fasciitis/heel spur syndrome⁽²⁾. In regard to the advantages of EPF, very little is known concerning its potential capability of correcting the recalcitrant plantar fasciitis via a single portal EPF without any special cutting device.

The aim of present study was to evaluate the

effectiveness of a modified uniportal EPF in a patient with severe intractable bilateral plantar fasciitis following failures of the conservative treatments. The recent technique; EPF with modified techniques were reviewed in an effort to improve its capability for medial plantar fasciotomy and to provide the guidance for the avoidance of this procedure's complications.

Case Report

A 49-year old female presented with medial heel pain of her both feet for a year. While her symptoms had been developing in last year, she was treated with oral medication and physical therapy due to a diagnosis as a plantar fasciitis, at the other hospital. Her symptoms were still worsening. The patient decided to visit our institute. A history taking and physical examination were performed again. Her medial heel pain associated with throbbing, especially with first few steps in the morning. The discomfort often limited her daily activities. The patient had tenderness around medial calcaneal tuberosity at the plantar aponeurosis of both feet. Weight-bearing radiographs showed the projection of inferior heel spurs: 8, 5 mm (in-length) with calcaneal pitch angle 5° , 10° on left and right foot, respectively (Fig. 1A, 1B). The plantar fasciitis and asymptomatic flatfoot were confirmed as final diagnoses. She received standard therapy for plantar fasciitis included analgesic medication, physical therapy and prescription orthoses for a month. However, the conservative treatments failed to provide relief. A patient decided to obtain the surgical treatment with EPF on both feet simultaneously, without spurs removal, which was preoperatively counseled about the advantages and potential complications. Informed consent was obtained from this patient for the procedures. The permission of the patient was obtained for this report. All data of the preoperative and each postoperative period (1, 6 and 9 months) were prospectively collected including clinical foot scores (Visual Analogue Scale-Foot and Ankle: VAS-FA; American Orthopaedic Foot and Ankle Society Score: AOFAS)^(6,7) and any related complications.

Surgical procedure

The surgical procedures were performed with the patient in a supine position with a padded tourniquet applied to the ipsilateral calf using proper anesthetic techniques. The calf was placed on a sterile rolled sheath at the distal rim of an operating table and each heel was placed beyond the edge of a table. This allowed comfortable access to the procedural site with

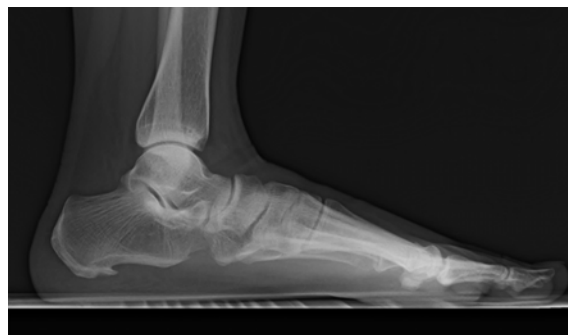

Fig. 1A A weight-bearing lateral radiograph showing the projection of the inferior heel spur: 8 mm (in-length) with calcaneal pitch angle 5° on left foot

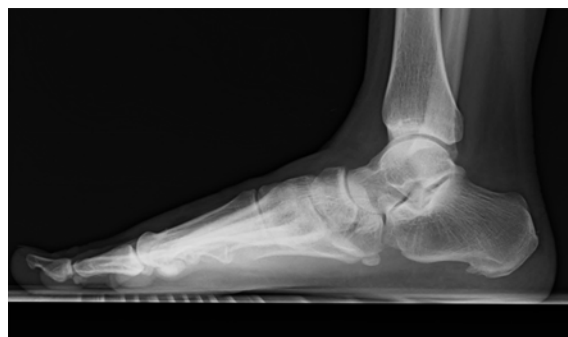

Fig. 1B A weight-bearing lateral radiograph showing the projection of the inferior heel spur: 5 mm (in-length) with calcaneal pitch angle 10° on right foot

surgical instrumentations. A big toe was dorsiflexed to identify the medial portion of the plantar fascia. A landmark of medial 50% of plantar fascia can be located and marked with a surgical pen before an incision (Fig. 2A). A 5-10 mm single oblique incision within the skin lines was made on the medial aspect of the foot, normally 1 cm distal to the medial tubercle of the calcaneus or a perpendicular line from the medial malleolus, just higher than the junction of the plantar skin (Fig. 2B)^(2,8). Once through the dermis, blunt dissection with a small scissor is performed through the subcutaneous tissue down to the level of the plantar fascia, avoiding neurovascular structures⁽⁸⁾. The fascial elevator is used to introduce a tract for the obturator/cannula which is inserted at the same plane after the elevator removal⁽⁸⁾. The proper tissue plane should provide minimal resistance during the insertion of the instruments. Once the correct tract was created, a 4-mm 30 degrees endoscope is placed and brought into a transverse position, which allows the scope to visualize closely underneath the plantar fascia (Fig. 3). After visualization

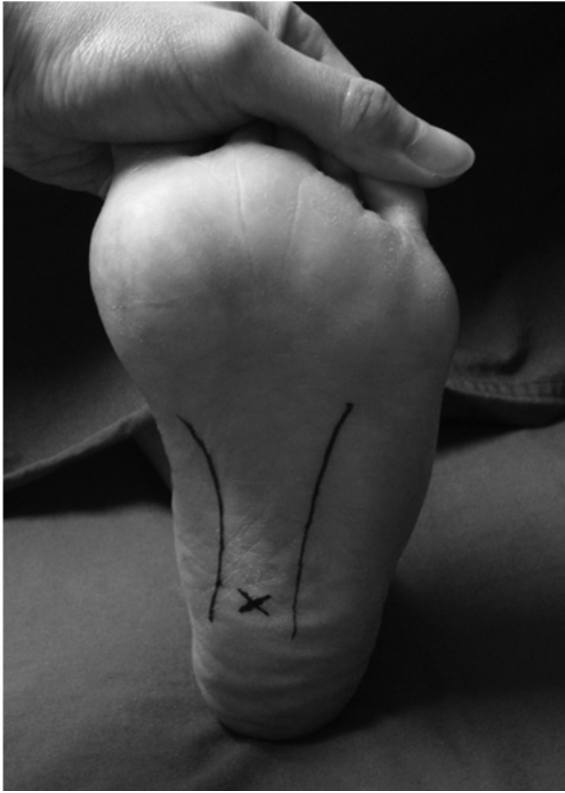

Fig. 2A The surface landmarks are demonstrated in the other patient (with permission). A big toe is dorsiflexed to identify the medial portion of the plantar fascia. A landmark of medial 50% of plantar fascia (X) is marked with a surgical pen before an incision

of the plantar fascia through the cannular slit, the scope could access through the whole length of the fascia. Care must be taken to ensure that there was no course of medial calcaneal nerve branch into the endoscopic field. The goal of the operation is to release the medial 50% of the plantar fascia completely. Then, a point of medial half of the fascial length can be identified by the compression by a surgeon's finger with a previous skin landmark with a surgical pen or by internally direct examination via the scope. The inserted length of a backward cutting blade (hook blade) is approximated as the same length of the scope inside the cannula at a point of medial half of the plantar fascia which is normally around 24.77 mm (Fig. 4)⁽¹⁾. This measured technique is our modified method to control the transection as only medial 50% of the plantar fascia using just a simple hook blade. Then, a hook blade is inserted with an approximated length from medial portal to lateral portion with the concomitantly retrograde

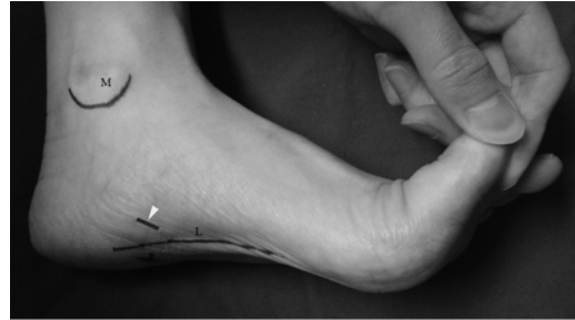

Fig. 2B The surface landmarks are demonstrated in the other patient (with permission). A 5-10 mm single oblique incision (arrow head) within the skin lines is planned on the medial aspect of the foot, generally 1 cm distal to the medial tubercle of the calcaneus or a perpendicular line from the medial malleolus, just higher than the junction of the plantar skin. A landmark of medial 50% of plantar fascia (X) is marked with a surgical pen before an incision. Medial malleolus (M) and medial rim (L) of the plantar fascia are outlined

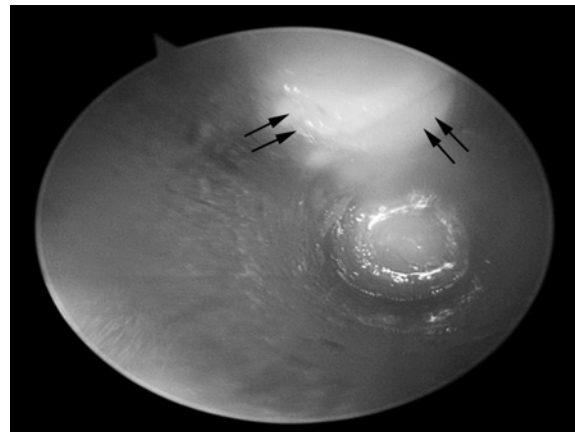


Fig. 3 The medial 50% of plantar fascia is visualized through the cannular slit (double arrows) after a 4-mm 30 degrees endoscope is placed and brought into a transverse position

removal of the endoscope according to our modified technique from Menon⁽⁹⁾. After the starting point to transect only a medial half of the fascia is confirmed with the approximated length including the external compression at a previously skin landmark, a medial 50% of the plantar fascia is transected in a retrograde fashion. At this cutting step, a surgeon requires to gradually adjust the depth of cutting level to the plantar fascia (mean of pathological thickness of plantar fascia: 5.71 ± 1.33 mm)⁽¹⁰⁾ to prevent the damages to the overlying muscle. Normally, the length of cutting-side

of a hook blade is less than the pathological thickness of plantar fascia. Therefore, a hook blade is safe to release a fascia provided that a surgeon uses it meticulously. Then, an endoscope is placed to examine and confirm the transection. If the planned fascial release is not completed, further resection is performed with gentle cutting as mentioned previously. Following the complete release of the medial half of the plantar fascia, the abductor hallucis muscle belly should be visible (Fig. 5). The rest of the one-half lateral portion of the plantar fascia may be confirmed by palpation at the external landmark or endoscopic examination. The irrigation is performed through the cannula, which is then removed. The skin incision is closed with a couple of 3-0 nylon sutures.

Postoperatively, a patient is advised to use a full-length silicone insole with medial arch support and kept partial weight bearing for 2 weeks. Then, sutures are removed at that time and she is allowed to start to fully weightbear with the insoles. She is advised to cautiously return to daily activities and works at 2nd week after the operation.

Results

Pre-postoperative clinical scores were as shown in Table 1. Her skin incisions were healed without complications (Fig. 6). She had pain-free heels at 2nd week after the operation then she could return to the normal function of the activity-daily livings. There were no significant iatrogenic-related complications included lateral column pain and neurovascular injuries. At final follow-up (9 months after the procedures), a patient's satisfaction was very high from her insight. Finally, she had no recurrences of the symptoms to inhibit her daily activities.

Discussion

There are several procedures for the plantar fascia release in patients with recalcitrant conditions of plantar fasciitis. These are open release, endoscopic partial fasciotomy, ultrasound-guided plantar fascia

release, etc^(2,11). Some of these traditional methods possibly accompanied by more tissue disruption and larger wound⁽¹¹⁾. These were the reasons that inspired us to carefully select the operative treatment for the recalcitrant plantar fasciitis utilizing a base procedure such as minimally invasive endoscopic plantar

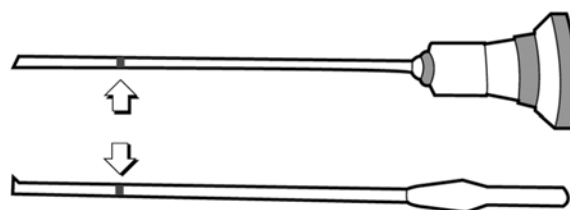


Fig. 4 The length of the endoscope (top) inside the cannula at a point of medial half of the plantar fascia is the same as the inserted length of a backward cutting blade (bottom). This length is normally around 24.77 mm from the tip of each instrument (markers: corresponding arrows)⁽¹⁾.

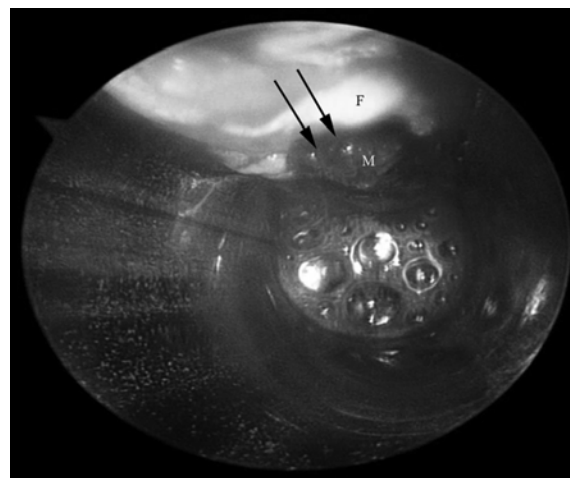


Fig. 5 The abductor hallucis muscle belly (M) is demonstrated clearly after complete release of the medial 50% of plantar fascia (the edge of plantar fascia after cutting: F). The medial rim of the muscle belly is shown (double arrows)

Table 1. Score results and the comparisons between the preoperative and postoperative periods

Side of involved foot	Score types	Preoperative	1-month postoperative	6-month postoperative	Last follow-up [^]
Right/Left*	AOFAS	52	82	87	100
	VAS-FA	41.5	73	95.76	100

*The authors' patient has the same levels of symptoms in both feet. [^]Last follow-up at 9 months after the operations

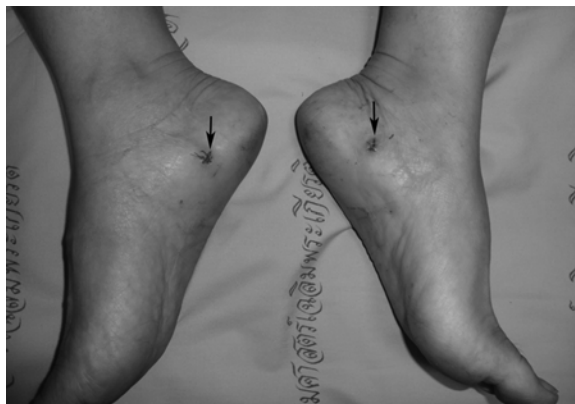

Fig. 6 The patient's skin incisions were healed without complications (arrows)

fasciotomy (EPF) which has a proven, encouraging track record for the release procedure. Regarding the subtypes of EPF, there are two main approaches as a double portal and single portal (or uniportal) approach. First approach is a double portal EPF which has been proposed about its techniques and results as more than 10 years^(1,4). Using this procedure, a surgeon needs both medial and lateral portal to visualize and transection of the plantar fascia. The results have been reported to be correlated with lower complications⁽⁴⁾ and a faster return to work⁽⁵⁾ compared to traditional procedure. However, this double portal EPF may produce some potential complications such as lateral incision scar, postoperative lateral foot pain or lateral column pain syndrome, etc^(2,12-14). At this point, the second approach is the uniportal EPF which has been developed to correct the downside of a double portal approach. The uniportal endoscopic plantar fasciotomy showed fewer complications⁽¹⁵⁾. The outcomes were satisfactory in athletic patients in terms of the shorter time to return to their sport⁽²⁾. Although the uniportal EPF seems to be more sound than a double portal EPF in terms of lower complications and invasiveness, its technique substantially depends on special instruments such as depth gauge device, a disposable cannulated knife (attached to the endoscope) and a stop device⁽²⁾. This may limit the reproducibility of the uniportal EPF in many centers where required special instruments are not available. This point encourages us to modify the novel technique of EPF to use for the plantar fascia release with just a simple cutting device as a backward cutting blade (hook blade). The novel technique of EPF with a simple hook blade has not been stated previously, to our knowledge.

Based on results in the present study, the

postoperative AOFAS and VAS-FA scores were satisfactorily improved comparing with preoperative scores. She could return to the normal function of daily activities at 2nd week after the procedure. There was no complaint of the lateral column pain throughout the follow-up period. These impressive results may be explained from the advantages of minimally invasive techniques of the plantar fasciotomy via uniportal endoscope which aims to preserve the surrounding soft-tissues such as adjacent muscle, subcutaneous fat, etc⁽¹⁵⁾. Regarding the cutting technique, the present study demonstrates the plantar fascia release via the retrograde cutting which helps reduce the incidence of over-cutting to the lateral fascial part. The one-half lateral portion of the plantar fascia could be well-preserved under the authors modified technique which might reduce the chance of lateral column pain after our procedures. Additionally, the uniportal EPF helps avoid the necessity of a lateral portal which may add an incisional scar or be also related with lateral column pain^(2,11-13). Although the authors' technique of the uniportal EPF may produce various advantages as mentioned previously, this technique needs the meticulously preoperative planning of the anatomic outline as shown previously in the technique section. Surgeons need to understand the surface landmark, width of the plantar fascia and the pathologic thickness of a plantar fascia before performing of the procedure^(1,10). At the cutting step, surgeons also need to adjust the depth of cutting level to the plantar fascia gradually to prevent the damages to the overlying muscle. These points are necessary to be kept in mind for surgeons who decide to use this technique.

Conclusion

The recalcitrant condition of severe plantar fasciitis is not uncommon for several orthopedic surgeons. Regarding the emerging of several minimally invasive procedures for this condition, the authors modified uniportal EPF with a simple device was encouraging as a treatment option in releasing the plantar fascia with satisfactory effectiveness and lower risks of complications.

Potential conflicts of interest

None.

References

1. Barrett SL, Day SV, Pignetti TT, Egly BR. Endoscopic heel anatomy: analysis of 200 fresh frozen specimens. *J Foot Ankle Surg* 1995; 34: 51-

- 6.
2. Saxena A. Uniportal endoscopic plantar fasciotomy: a prospective study on athletic patients. *Foot Ankle Int* 2004; 25: 882-9.
3. El Shazly O, El Hilaly RA, Abou El Soud MM, El Sayed MN. Endoscopic plantar fascia release by hooked soft-tissue electrode after failed shock wave therapy. *Arthroscopy* 2010; 26: 1241-5.
4. Kinley S, Frascone S, Calderone D, Wertheimer SJ, Squire MA, Wiseman FA. Endoscopic plantar fasciotomy versus traditional heel spur surgery: a prospective study. *J Foot Ankle Surg* 1993; 32: 595-603.
5. Tomczak RL, Haverstock BD. A retrospective comparison of endoscopic plantar fasciotomy to open plantar fasciotomy with heel spur resection for chronic plantar fasciitis/heel spur syndrome. *J Foot Ankle Surg* 1995; 34: 305-11.
6. Kitaoka HB, Alexander IJ, Adelaar RS, Nunley JA, Myerson MS, Sanders M. Clinical rating systems for the ankle-hindfoot, midfoot, hallux, and lesser toes. *Foot Ankle Int* 1994; 15: 349-53.
7. Anghong C, Chernchujit B, Suntharapa T, Harnroongroj T. Visual analogue scale foot and ankle: validity and reliability of Thai version of the new outcome score in subjective form. *J Med Assoc Thai* 2011; 94: 952-7.
8. Saxena A. Endoscopic plantar fasciotomy. In: Maffulli N, Easley M, editors. *Minimally invasive surgery of the foot and ankle*. London: Springer-Verlag; 2011: 277-88.
9. Menon J. Endoscopic carpal tunnel release: preliminary report. *Arthroscopy* 1994; 10: 31-8.
10. Mahowald S, Legge BS, Grady JF. The correlation between plantar fascia thickness and symptoms of plantar fasciitis. *J Am Podiatr Med Assoc* 2011; 101: 385-9.
11. Vohra PK, Japour CJ. Ultrasound-guided plantar fascia release technique: a retrospective study of 46 feet. *J Am Podiatr Med Assoc* 2009; 99: 183-90.
12. Brekke MK, Green DR. Retrospective analysis of minimal-incision, endoscopic, and open procedures for heel spur syndrome. *J Am Podiatr Med Assoc* 1998; 88: 64-72.
13. Brugh AM, Fallat LM, Savoy-Moore RT. Lateral column symptomatology following plantar fascial release: a prospective study. *J Foot Ankle Surg* 2002; 41: 365-71.
14. Gentile AT, Zizzo CJ, Dahukey A, Berman SS. Traumatic pseudoaneurysm of the lateral plantar artery after endoscopic plantar fasciotomy. *Foot Ankle Int* 1997; 18: 821-2.
15. Jeran D, McElgun T, Mirza A, King E. Single portal endoscopic plantar fascial release: operative technique with preliminary results. *Lower Extrem* 1997; 4: 103-7.

รายงานวิธีการผ่าตัดส่องกล้องแบบดัดแปลงโดยใช้ทางเข้าเดียวในผู้ป่วยที่มีเอ็นพังผืดสันเท้าอักเสบแบบเรื้อรัง

ชญาณีน อ่างทอง, ชัชวาลย์ เจริญธรรมรักษา, สุคนิศา ฉ่ำชื่น, ศุภกกิจ คณิตเนตร, อนุวัฒน์ ชัดสงคราม,
วิรณา อ่างทอง

วัตถุประสงค์: ปัจจุบันมีการรายงานทางการแพทย์จำนวนมากที่กล่าวถึงประโยชน์จากการผ่าตัดส่องกล้องแบบ 2 ทางเข้า สำหรับการตัดระบายเอ็นพังผืดสันเท้า อย่างไรก็ตามมีข้อมูลน้อยมากที่อธิบายถึงประโยชน์จากการผ่าตัดส่องกล้อง แบบทางเข้าเดียวโดยไม่จำเป็นต้องใช้อุปกรณ์พิเศษ รายงานฉบับนี้มีจุดประสงค์เพื่อบอกถึงประโยชน์, วิธีการและข้อควรระวังของการผ่าตัดส่องกล้องแบบทางเข้าเดียวที่ได้ดัดแปลงใหม่เพื่อให้ไม่จำเป็นต้องใช้อุปกรณ์พิเศษร่วม

รายงานผู้ป่วย: ผู้ป่วยหญิงอายุ 49 ปี มาด้วยอาการและอาการแสดงของภาวะเอ็นพังผืดสันเท้าทั้ง 2 ข้างที่อักเสบอย่างหนักแบบเรื้อรังโดยรักษาด้วยวิธีอนุรักษนียมมาแล้วเป็นเวลา 13 เดือน และอาการไม่ดีขึ้น ผู้ป่วยจึงตัดสินใจเข้ารับการผ่าตัดส่องกล้องแบบทางเข้าเดียวที่ได้ดัดแปลงใหม่นี้กับสันเท้าทั้ง 2 ข้าง ในการผ่าตัดครั้งเดียวกัน โดยผู้ป่วยได้รับการอธิบายให้รับทราบและเข้าใจเกี่ยวกับขั้นตอน-ประโยชน์และภาวะแทรกซ้อน จากหัตถการดังกล่าวก่อนเข้ารับการผ่าตัด ทั้งนี้ข้อมูลพื้นฐานของผู้ป่วยรวมทั้งคะแนนของอาการเท้า-ข้อเท้า (American Orthopaedic Foot and Ankle Society (AOFAS) score, Visual Analogue Scale-Foot and Ankle (VAS-FA) score) และภาวะแทรกซ้อนที่เกี่ยวข้องจะได้รับการบันทึกก่อน-หลังผ่าตัด (1 เดือน, 6 เดือน, การติดตามอาการครั้งล่าสุด) อย่างละเอียด สำหรับการผ่าตัดนั้นศัลยแพทย์ได้ปรับใช้มีดตัดแบบตะขอร่วมกับการส่องกล้องเพื่อให้ไม่จำเป็นต้องใช้อุปกรณ์พิเศษอื่นๆ ร่วมในการตัดระบายเอ็นพังผืดที่มีพยาธิสภาพอยู่ทางด้านใน (medial) ที่ความกว้าง 50% ของความกว้างของเอ็นพังผืดทั้งหมด ช่วงหลังผ่าตัดผู้ป่วยได้รับคำแนะนำให้ใส่อุปกรณ์เสริมฝ่าเท้าและลงน้ำหนัก บางส่วนเป็นเวลา 2 สัปดาห์ หลังผ่าตัด จากนั้นสามารถเริ่มลงน้ำหนักได้เต็มที่ และทำกิจวัตรประจำวันหรือทำงานทั่วไป ได้ด้วยความระมัดระวังต่อไป ผลของการผ่าตัดเป็นที่น่าพอใจอย่างมาก โดยคะแนนเท้า-ข้อเท้าทั้ง 2 แบบ ดีขึ้นชัดเจน นอกจากนี้ผู้ป่วยไม่มีภาวะแทรกซ้อนใดๆ หลังผ่าตัดจากการติดตามผลการรักษาโดยตลอด

สรุป: ภาวะเอ็นพังผืดสันเท้าที่อักเสบอย่างหนักแบบเรื้อรังที่รักษาด้วยวิธีอนุรักษนียมมานานแล้ว และอาการไม่ดีขึ้นนั้น เป็นภาวะที่พบได้ในเวชปฏิบัติทั่วไปทางกระดูกและข้อ จากการที่มีการพัฒนามากขึ้นในปัจจุบันสำหรับการผ่าตัดแบบส่องกล้อง และการผ่าตัดแบบจำกัดขอบเขตของการผ่าตัดนั้น รายงานฉบับนี้ได้แสดงถึงวิธีการผ่าตัดส่องกล้องแบบทางเข้าเดียวที่ได้รับการดัดแปลงเพิ่มเติมและเสนอให้เป็นทางเลือกหนึ่ง ในการรักษาภาวะเอ็นพังผืดสันเท้าอักเสบแบบเรื้อรังดังกล่าวที่มีประสิทธิภาพเป็นที่น่าพอใจและมีความเสี่ยงต่อการเกิดภาวะแทรกซ้อนน้อย
